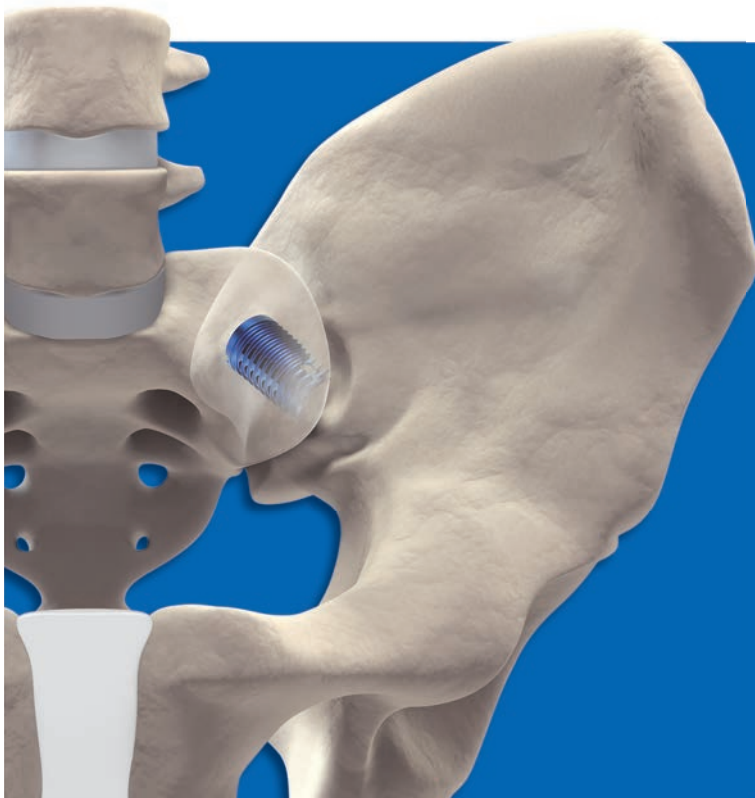

# DIANA®

Distraction-Interference-Arthrodesis with Neurovascular Anticipation



**One screw**  
**Gentle access**  
**Targeted placement**



PRODUCT INFORMATION

# PRODUCT INFORMATION



## Content

---

### General

---

Sacroiliac joint	4
Implant	5
Requirements for a successful procedure	7
Surgical training	8

### Diagnostics and medical history

---

Diagnosis	9
Medical history and diagnostics	11
Diagnostic algorithm for surgical decision making	12
Pain provocation tests	13
Computed tomography	14

### Preparing for the operation

---

Ordering information	16
Checklist for the operation	17
Instruments	19
Checklist of additional instrumentation	20

### Operation sequence with DIANA

---

Preparing for the operation	21
Intraoperative imaging	24
Aligning the fluoroscope	25
Required images	26
Positioning	27
<b>Surgical technique</b>	<b>29</b>

### Follow-up treatment

---

Sample operative report	34
Postoperative treatment	35
Case study	36

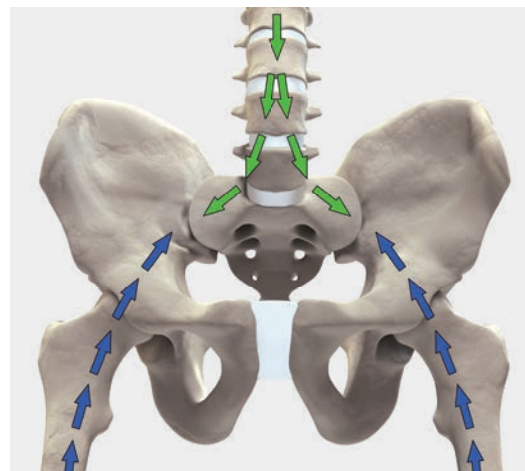
# PRODUCT INFORMATION

## Sacroiliac joint

The sacroiliac joint SIJ is a load-bearing joint between the ilium and the sacrum. It is a true joint that has osseous subchondral surfaces, articular cartilage and ligamentous structure.

Although the SIJ makes only minor translational and rotational movements, over the course of a lifetime it can develop signs of wear. The reason for this is its position in the weight-bearing axis where it is exposed to large compression and shear forces.

During diagnosis, procedure, and postoperative care, fusion of the sacroiliac joint consistently presents a challenge. Therapists should therefore be knowledgeable, experienced and thoroughly trained.

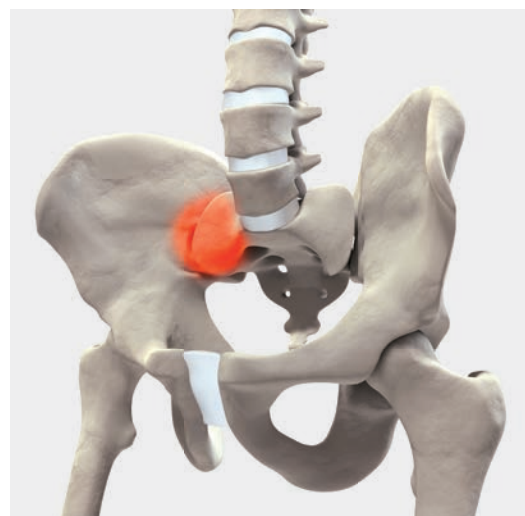


### → Fusion of the SIJ

Within the pelvis the mechanical axis is responsible for the position of the joint, which is specified by the converging axes of the lower extremities. The deep location of the anatomical structures make surgical access difficult.

Arthrodesis of the sacroiliac joint should only be considered if conservative therapies are not effective, pronounced pain persists and all contraindications have been excluded.<sup>1</sup>

Responsible use of the DIANA method is particular important. SIGNUS therefore offers detailed professional training that covers all aspects of the procedure from determining indications to assessing surgical outcomes. SIGNUS also supports the new user throughout the learning process.



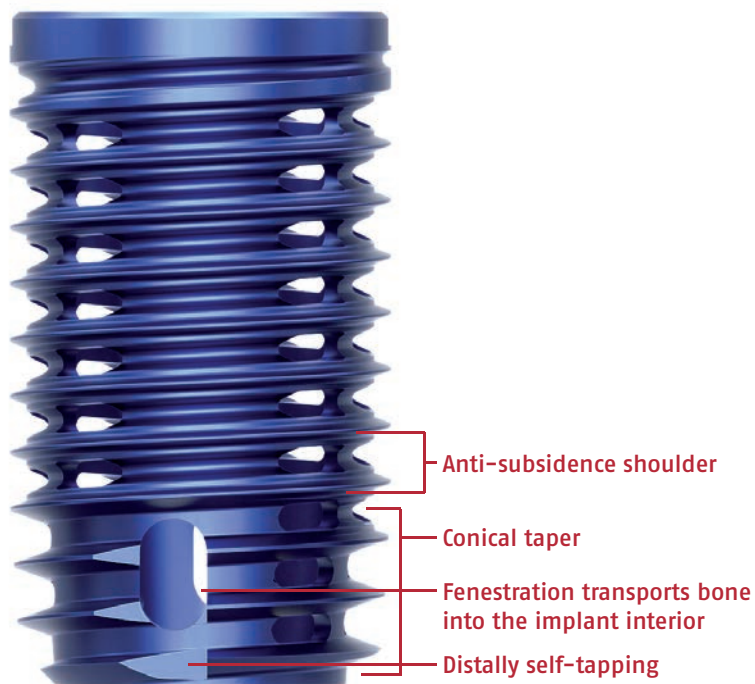
<sup>1</sup> Lorio MP, Rashbaum R.: ISASS policy statement – minimally invasive sacroiliac joint fusion. (Int J Spine Surg. 2014 Dec 1;8. Updated March 15, 2015)

## Implant

---

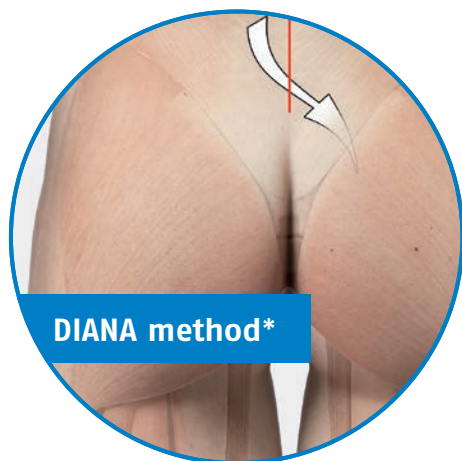
The implant design has the following characteristics:

- Hollow interference screw made of titanium Ti6Al4V
- Multifunctional thread profile has proximal shoulder to resist subsidence
- Multifunctional, conical section is self-tapping and distracting
- Large central cavity for bone graft
- Fenestrations for bony union
- Easy to revise



# PRODUCT INFORMATION

## Implant



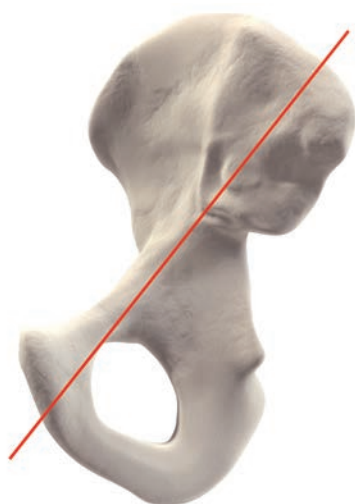\* 3D example, not suitable for anatomical teaching purposes.

### Distraction Interference Arthrodesis

In an atraumatic and low-risk procedure, the DIANA method anchors an interference implant via a posterior access distally in the iliac bone. The proximal and central part of the implant is located in the extra-articular recess without affecting the actual articular surfaces.

The surgical access to the recess and the path of the instruments and implant follow the iliac diaphysis and thus the weight-bearing axis of the pelvis. The intraoperative radiographic images are adjusted taking this axis into consideration. The transition of the bony segments of S1 and S2 thus forms the entry point for the guide wire and the instruments, the trajectory of which travels from this point towards the hip joint.

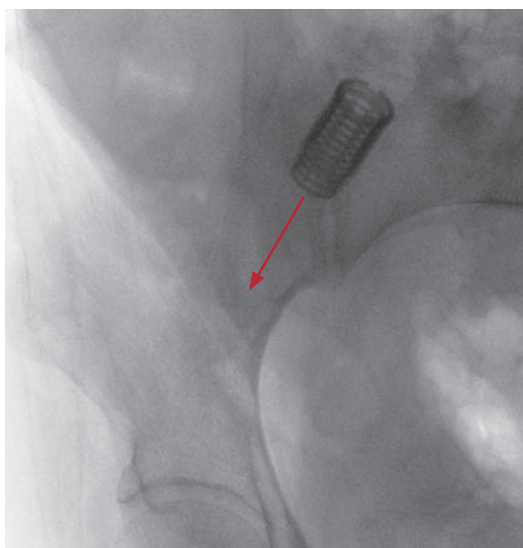
The joint space is then distracted during the procedure, relieving stress on the joint cartilage as well as capsular neural structures and those neural structures immediately anterior to the joint. It is thus possible to approximate the original state of the pelvic girdle using ligamentotaxis. The entire procedure is carried out within a safe access zone with no weakening of the musculature or the bony structures. Retraction and revision are still entirely possible.



Trajectory of the guide wire.

#### Note

Permanent fusion is achieved by thorough preparation, targeted debridement of the iliac and sacral cortical bone in the recess, and apposition of bone material in both the extra-articular recess and in the implant.



## Requirements for a successful procedure

---

The surgical procedure using DIANA is designed in such a way that there are anatomical and physiological safety margins. Nevertheless, the surgeon should assess each patient individually to determine whether the method can be safely used.

### **Preoperative examinations (minimum requirements):**

1. General physical examination (including abdomen, spine, and hips)
2. Imaging
  - a) Radiography of the pelvis AP
  - b) MRI of the lumbar spine and, if appropriate, the pelvis
  - c) CT of pelvis and SIJ
  - d) If appropriate, SPECT-CT
3. Laboratory analyses
  - a) Routine preoperative program to prepare for major skeletal surgery
  - b) If appropriate, measurement of the vitamin D level
  - c) If appropriate, DXA measurement

In the following cases, the operation should not be carried out or should be interrupted:

1. Insufficient or lack of compliance with the therapy by the patient
2. Pronounced osteoporosis, impaired bone metabolism or expected impaired healing process
3. Bone defects in the iliac bone or the sacral bone due to previous procedures
4. Tumors or inflammations in the bony pelvis
5. Repeated failed attempts to fuse the SIJ

### **The role of the patient in the success of the procedure**

---

It is necessary to include the patient in the entire therapeutic process. This also includes providing information about healing requirements, surgical decision making, and accepting the risks. The surgeon must know the intended treatment path and the prospects for success and be able to understandably explain both. This is only possible when all elements of the particular disease process are examined and known.

Psychosocial factors can play just as important a role in the success of the procedure as the entire disease progression, including chronic pain and possible depression.

Surgery using the DIANA method lies at the end of the therapeutic protocol. Although it is a low-risk surgical treatment option, optimal treatment outcomes cannot be guaranteed in every case. Patients should be aware of this. The procedure may be followed by a long healing phase with varying pain progression. Negative effects on the personal, social or economic situation are also possible in many cases. Doctors should always take these factors into consideration and discuss them during the consultation.

## Surgical training

---

### Theory

---

SIGNUS is here for you!

We will be by your side while you learn the DIANA method until you and your team feel comfortable with the procedure.

At our regular training events, you first learn the theoretical foundation of the DIANA procedure – from the biomechanics of the SIJ, to determining the indication and conservative treatment options, to assessment of the surgical results. Then, you will learn the practical application of DIANA.

For your first DIANA operations, we provide a tutor to observe and assist who is completely familiar with the DIANA procedure and will give you valuable tips and tricks throughout the whole process. In addition our DIANA support staff will also train your surgical personnel and accompanies them with their subsequent cases until they are comfortable with the procedure.

Of course, your tutor and the DIANA support staff are available to address any questions regarding indications, surgical technique and assessment of surgical results. There is also the opportunity to observe a DIANA procedure at one of our reference centers.



## Diagnosis

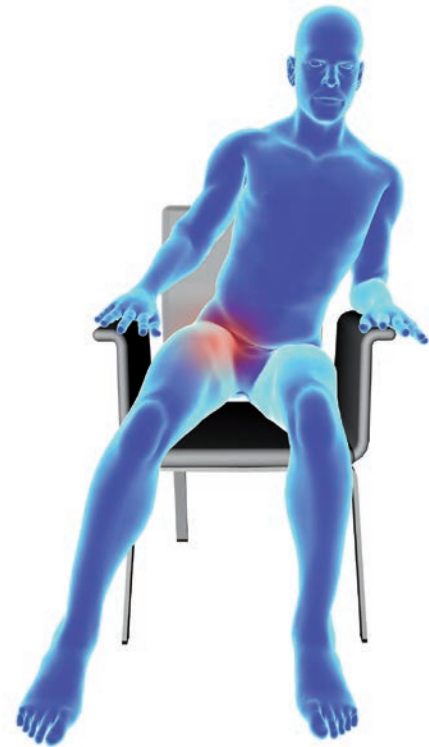---

Before planning the procedure the sacroiliac joint must be unambiguously identified as the source of the pain.

Because the SIJ is part of an anatomical complex made up of the spine and lower extremities, the doctor must consider other possible causes of pain in adjacent structures. As well as the SIJ, the spine and/or the hip joints are often also affected. It is therefore necessary to perform comprehensive clinical evaluation and diagnostics to identify the source of the pain. Due to mechanical or radicular symptoms, the SIJ can also mimic conditions in the lumbar spine and/or the hip joints. The reverse is also true.<sup>1</sup>

Treatment of pathological findings may therefore include one or multiple operations.

The neurovascular structures surrounding the SIJ are fundamentally involved in the disease process in the joint. The surgeon and his or her team should be aware of the complex interrelationships and make use of all necessary non-invasive and invasive diagnostics and therapeutic options before considering surgery.



Typical seated position with SIJ pain (pain on the right side).

---

<sup>1</sup> Lorio MP, Rashbaum R.: ISASS policy statement – minimally invasive sacroiliac joint fusion. (Int J Spine Surg. 2014 Dec 1;8. Updated March 15, 2015)

# PRODUCT INFORMATION

## Medical history and diagnostics

Last name:  First name:   
Date of birth:  Date:

1. Sex:  Male  Female

Weight:  kg

Height:  cm

BMI:

2. Affected side (clinically more painful):  right  left  bilateral

3. Symptoms have been present since:

4. Previous spinal/SIJ surgery; what:

when:

Are there pedicle screws in S1?  right  left  bilateral

5. Previous conservative therapy:

Denervation [RF] [cryo]

Orthosis

Physiotherapy

Other:

6. PSIS diagnostics:

Pain diagram:  typical  atypical

Patrick test:  right  left  bilateral  no

Tenderness to palpation over SIJ:  right  left  bilateral  no

Sitting intolerance:  right  left  bilateral  no

7. Pain medication (drug/dosage /duration):

NSAIDs:

Opioids:

Opiates:

8. Smoker  yes  no

How long (years):

Number of cigarettes/day:

**9.** What is the patient's current working situation?

Not employed  
 Current retirement application process  
 Early retirement  
 Retirement  
 Employed, please specify:

**10.** Last practiced employment/profession:

Specify the work activities:

Not physically active  
 Light physical activity  
 Heavy physical activity

**11.** What is the problem attributed to?

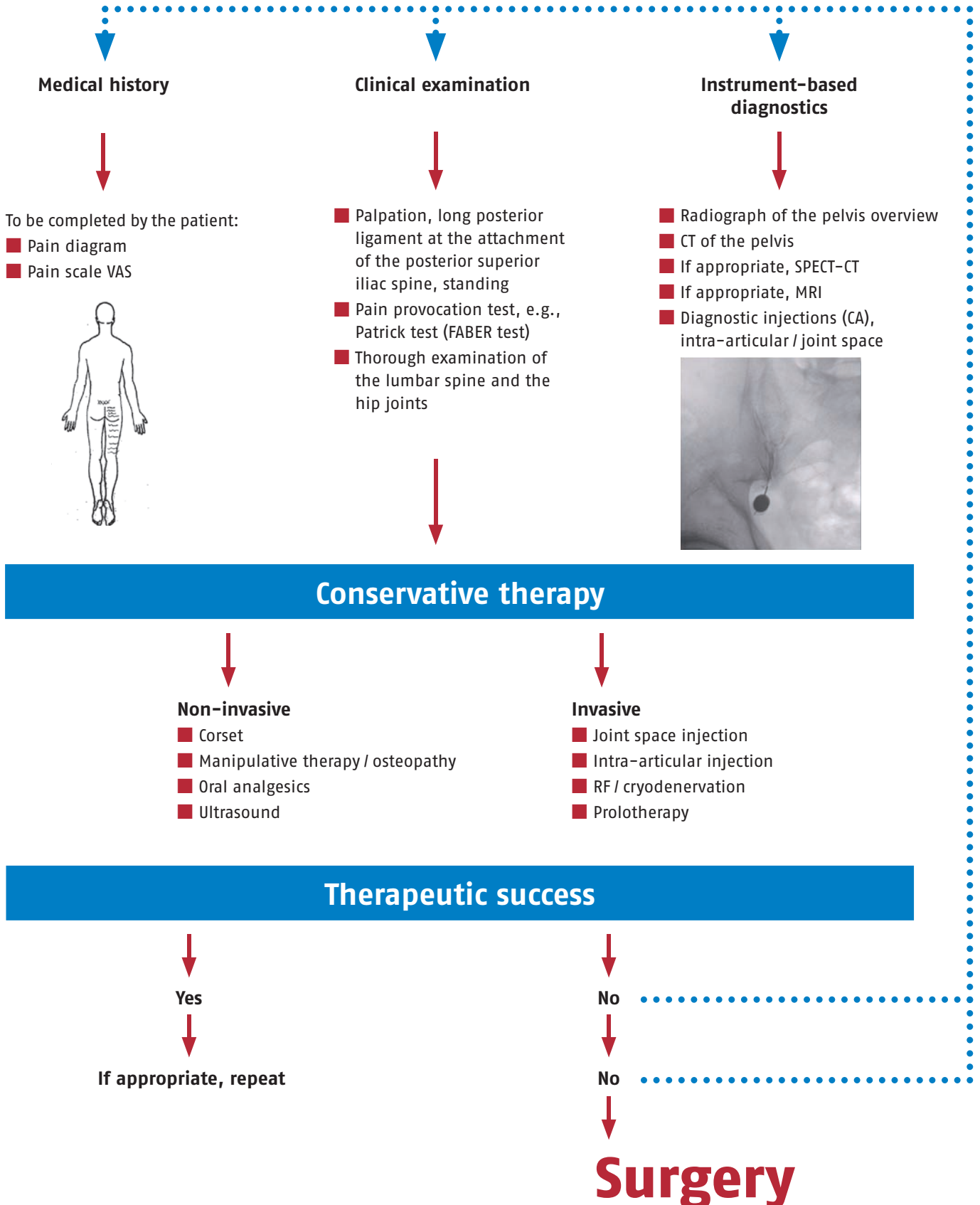
Accident  
 Pregnancy  
 Previous OP  
 Rheumatism  
 Degeneration  
 Not known  
 Other cause, please specify:

**12.** Comments

A print version of this document can be found in the download area of our homepage [www.signus.com](http://www.signus.com).

# PRODUCT INFORMATION

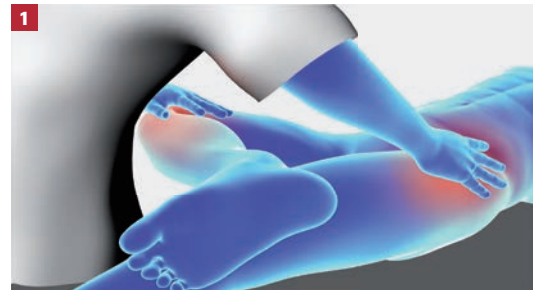
## SIJ: Diagnostic algorithm for surgical decision making



## Pain provocation tests

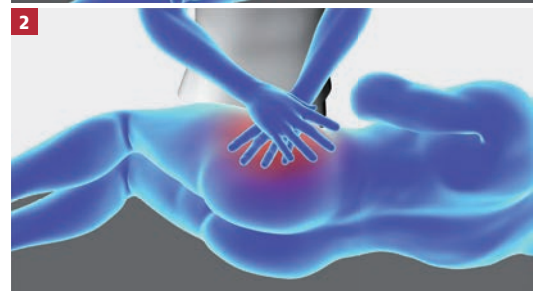
### Patrick test (FABER test)

The patient is placed in a supine position. One leg is flexed, abducted, and rotated outwards (FABER: Flexion, Abduction, External Rotation) and the ankle is placed on the contralateral knee. The therapist stabilizes the contralateral iliac wing to the anterior superior iliac spine (ASIS) and then exerts a slight overpressure on the knee in the abducted position. **1**



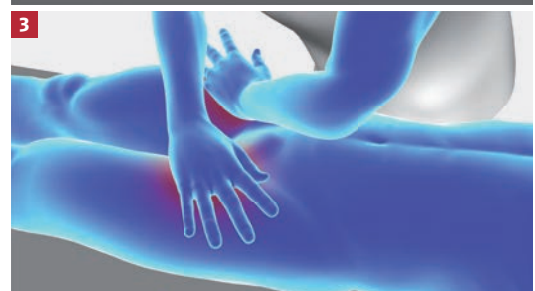
### Compression test

The patient is placed in a lateral position. The therapist exerts vertical downward pressure with both hands on the upper iliac crest. The posterior ligaments of the SIJ should be stretched by this test and be compressed anteriorly. **2**



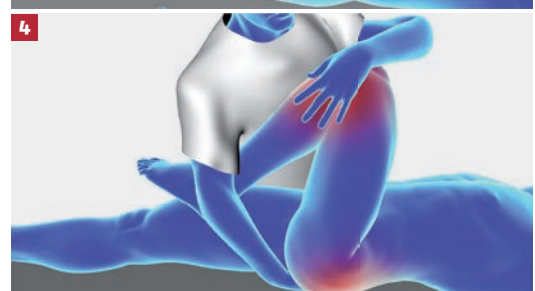
### Distraction test (gapping test)

The patient is placed in a supine position. The therapist presses with his or her hands both anterior superior iliac spines (ASIS) in a posterolateral direction. The anterior ligaments of the SIJ should be stretched by this test and be posteriorly compressed. **3**



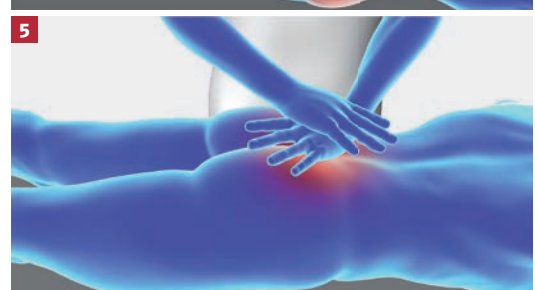
### Thigh thrust (posterior shear, P4 test or posterior pelvic pain provocation test)

The patient is placed in a supine position. The therapist holds the opposite leg in 90-degree hip joint flexion and stabilizes the sacrum with the other hand (to act as a hypomochlion). The vertical femur produces a shearing force in the SIJ. **4**



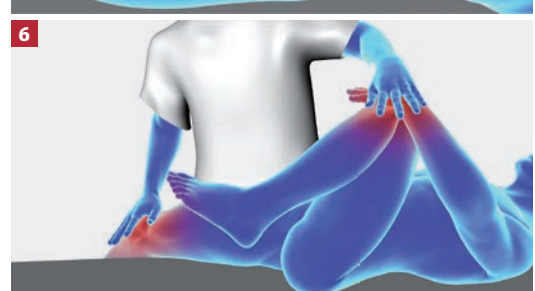### Sacral thrust

The patient is placed in a prone position. The therapist applies a vertical, pulse-like anteriorly directed pressure over the sacrum. **5**



### Gaenslen's test (pelvic torsion)

The patient is placed in a supine position with the affected leg hanging over the edge of the examination bench. The other leg is flexed to the end of the range of movement at the hip and is stabilized by the therapist. Applying overpressure to the extended leg achieves rotation of the ilium relative to the sacrum and ilium. **6**

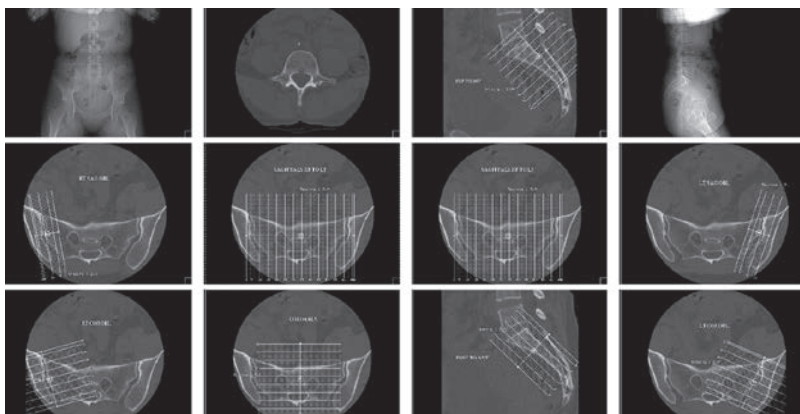


# PRODUCT INFORMATION

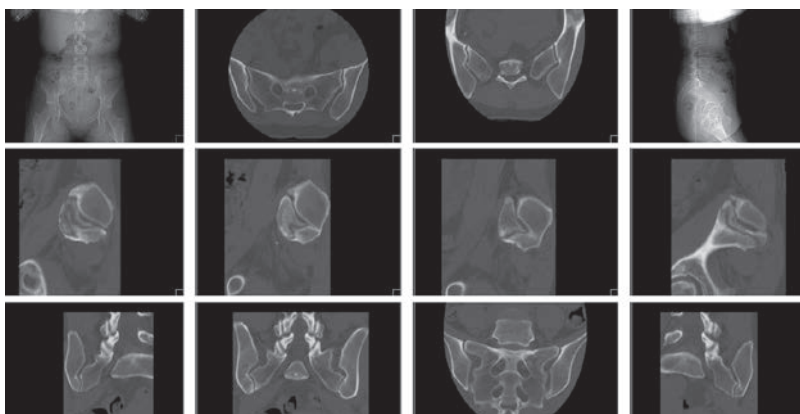
## Computed tomography

### CT imaging for pathological evaluation of the sacroiliac joint

Imaging and assessing the sacroiliac joint by CT requires time and experience. It presents a new challenge to many radiologists and spinal surgeons.

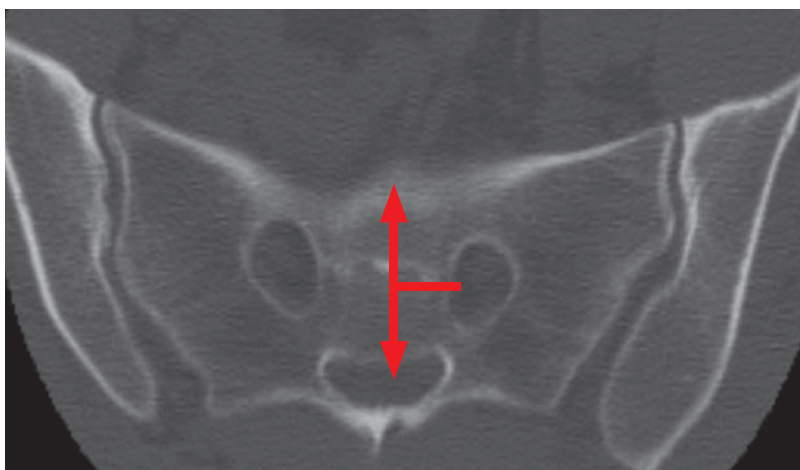


SIGNUS can prepare reconstructions for you using your images. Please send the images directly to your DIANA tutor. Ensure that all patient data are anonymized before you send the images to SIGNUS.



#### Basic images

To exclude any pathologies that are located higher and that are only projecting onto the SIJ, images in the axial plane in the bone window from L4 to the femoral heads should be taken with a maximum slice thickness of maximal 1.5 to 2.0 mm.

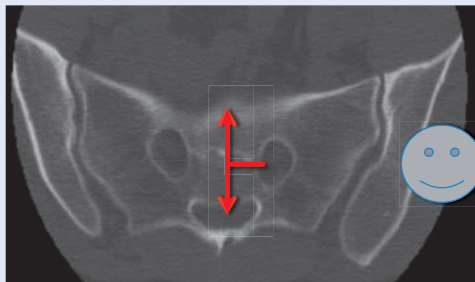




## Diagnosis of pathological changes of the sacroiliac joint in CT

Dr. Volker Fuchs M.D., AMEOS Hospital, Halberstadt (Germany)

1. CT slice thickness: 1.5 – 2.0 mm; bone window (W 3200, L1000, Filter D)
2. Axial slices from lumbar spine segment 4 down to the upper edge of the greater sciatic notch

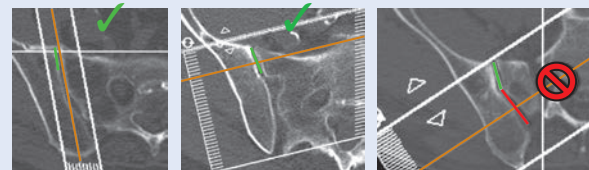


3. Reconstruction of additional sectional planes at the height of the S1 neural foramen where it is projected at one half the distance from the spinal canal to the anterior sacral margin.

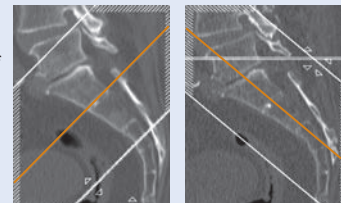
4. In addition to simple axial, sagittal and coronal reconstructions, reconstruction levels are provided parallel or perpendicular to the angle of the oblique SIJ for improved depiction:

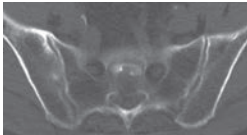
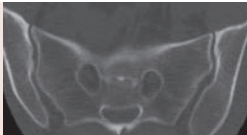
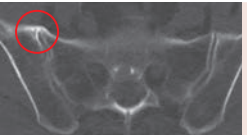
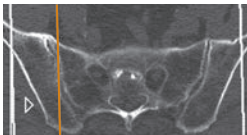


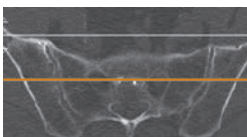
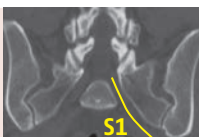
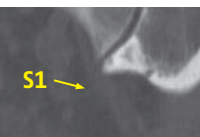
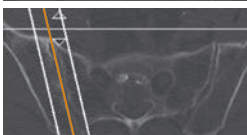

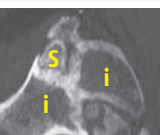
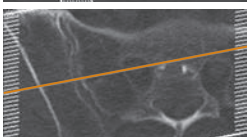

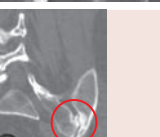



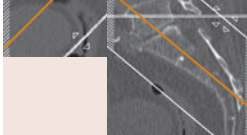
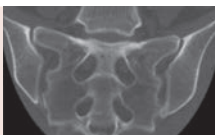

● parasagittal ● paracoronal ● paraxial ● sacral-coronal

5. Planning of parasagittal or paracoronal sectional planes parallel or perpendicular to the actual joint (green line), not to the recess (red line)



6. Orientation of paraxial or sacral coronal reconstructions parallel to the base or cover plate of S1/S2 or perpendicular to this green line



	Normal finding	Osteoarthritis
 <p><b>Axial slices</b> should additionally include the spinal segments L4 and L5 for differential diagnosis</p>		
 <p><b>Sagittal slices</b> (here: right) show, in addition to the dorsal recess of the SIJ, the facet-like interlocking of the sacral bone and the iliac bone</p>		
 <p><b>Coronal slices</b> depict the caudal section of the SIJ together with facet joints L4/5 and L5/S1; good depiction of the recess size right/left; The S1 root is fully traceable from the spinal canal to the SIJ</p>		
 <p><b>Parasagittal slices</b> (here: right) run as parallel as possible to the SIJ and show the interlocking from the iliac bone to the sacral bone</p>		
 <p><b>Paracoronal slices</b> (here: right) show a true cross-section through the SIJ as well as its dorsal recess; the course of nerve root L5 and S1 along the ventrocaudal section of the SIJ can often be recognized, as well as causes of possible irritation (such as osteophytes) at this location</p>		
 <p><b>Paraxial slices</b> depict the anterior and posterior neural foramina of the sacral bone in one level and in particular show their proximity of the dorsal recess</p>		
 <p><b>Sacral coronal slices</b> show the transverse processes of the sacral bone and the upper as well as lower sections of the recess instabilities in the SIJ are reflected as incongruities in the form of an intraarticular vacuum phenomenon</p>		

# PRODUCT INFORMATION

## Ordering information

---

### Implants

Art. No.	Description	Ø (mm)	Length (mm)
SJ1312	DIANA IF Implant	13/12	30
SJ1514	DIANA IF Implant	15/14	30
SJ1716	DIANA IF Implant	17/16	30
SJ1918	DIANA IF Implant	19/18	30
SJ2119	Revision implant	(only on request)	



After careful preparation of the fusion surfaces, the fusion is completed by placement of the graft material. SIGNUS recommends using autograft and/or allograft.

#### Caution

Consider homologous cancellous bone when ordering!



## Checklist for the operation

### Operating table

To ensure reliable intraoperative radiological imaging the operating table should be reviewed with respect to the following criteria:

- How much metal is in the operating table? Where is it?
- How far can the operating table move at the head and foot ends?
- Where is the support column?
- Is the table made of carbon fiber?
- Is the table partly or completely made of carbon fiber?

#### Caution

Be aware of any metal rails or supports between the carbon fiber sections!

### Positioning aids

To ensure correct positioning of the patient, ensure that the following positioning aids are available:


- Spinal frame
- VAC cushions 60 × 80cm
- Thoracic cushions
- Leg/foot bolster
- Knee gel cushions
- Various gel cushions

### Fluoroscope

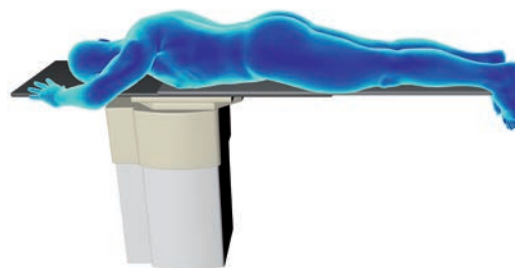
It is important to check how far the fluoroscope can be rotated around the operating table. It is best if it can be rotated at least 30° to 35° from vertical.

### Microscope

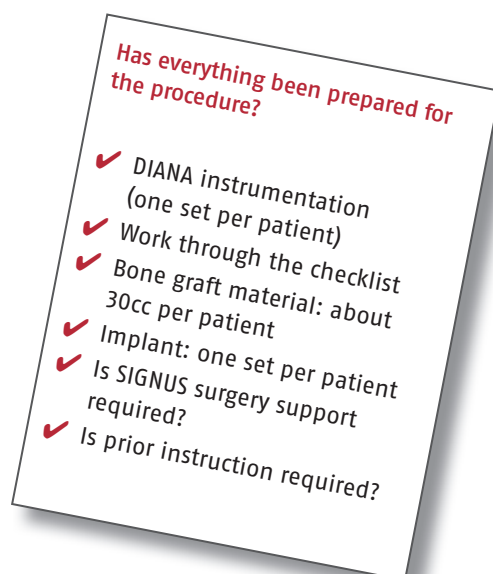
For optimal visualization of the recess it is essential to use a microscope during the dissection.



Correct patient positioning on a standard operating table with metal braces.



Correct patient positioning on a carbon fiber table.



# PRODUCT INFORMATION

## Instruments

The instruments are arranged in the order in which they will be used in two sterilization trays.

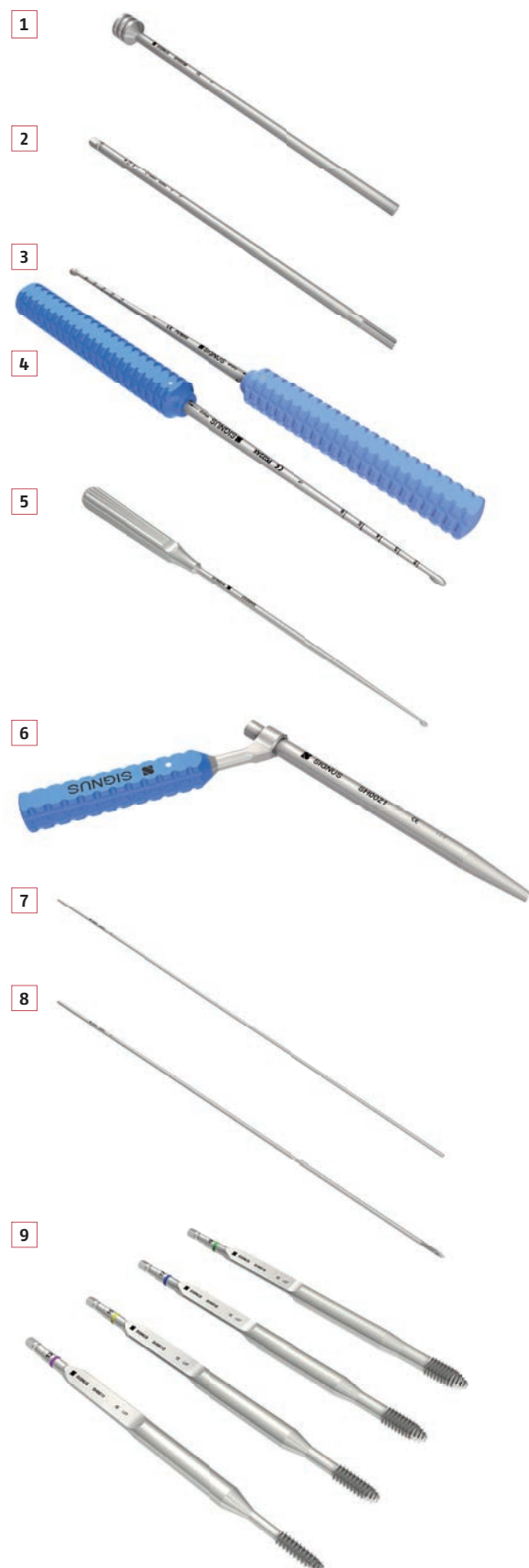Tray #1 contains the instruments for dissection and preparation for fusion.

Fig.	Art. No.	Description
1	SH0038	Graft impactor
2	SH0042	Pre-Cutter
3	PO22AX	Bone curette, straight
4	PO19AX	Bone curette, straight
5	SH0037	Bone curette, small (300 mm)
6	SH0021	Drill Guide
7	SH0022	Guide Pin, blunt 2.4mm
8	SH0023	Guide Pin, threaded
9	SH0011	Helio (recess screw) 13/12 mm
	SH0012	Helio (recess screw) 15/14 mm
	SH0013	Helio (recess screw) 17/16 mm
	SH0014	Helio (recess screw) 19/18 mm
10	T001AQ	Mallet
11	SH0030	T-Handle fixed; 1/4"

The distraction achieved with the helio determines the diameter of the subsequent instruments which are color-coded by size and grouped in Tray #2 by color.

Fig.	Art. No.	Description
12	SH0020	Trajector Inserter
13	SH0019	Trajector Sleeve
14	SH0015	Trajector 13 mm
	SH0016	Trajector 15 mm
	SH0017	Trajector 17 mm
	SH0018	Trajector 19 mm
15	SH0024	Sliding Hammer
16	SH0010	Depth stop
17	SH0006	Reamer 13 mm
	SH0007	Reamer 15 mm
	SH0008	Reamer 17 mm
	SH0009	Reamer 19 mm
18	SH0001	Inserter 13 mm
	SH0002	Inserter 15 mm
	SH0003	Inserter 17 mm
	SH0004	Inserter 19 mm

Optional (no image)	
SH0033	Harvester
SH0033-2	Harvester, shaft
SH0033-3	Protection sleeve
SH0033-1	Reamer for harvester
SH0043	Bone biopsy trephine



10



15



11



16



12



17



13



18



14



# PRODUCT INFORMATION

## Checklist of additional instrumentation

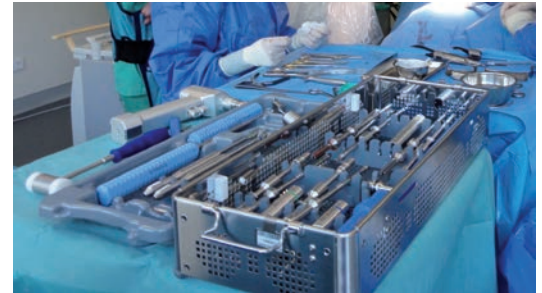In addition to the DIANA instrumentation, only a few additional instruments that are found in every operating theater as standard instruments are required for surgery using the DIANA method. To efficiently set up the preparation and reprocessing of the instruments, SIGNUS recommends assembling the following equipment and materials:

### General preparation

- ✓ Sterile drape, gown, sterile gloves
- ✓ Fluoroscope cover
- ✓ Microscope cover
- ✓ Sterile light handles or light handle covers
- ✓ Suction
- ✓ 4x 5ml syringes
- ✓ Sterile pen and ruler
- ✓ Fusion material (homologous bone graft)
- ✓ Thick felt pen (Edding) and long non-sterile K wire for planning incision

### Basic instrumentation

- ✓ Skin prep set – dressing forceps
- ✓ 2 metal basins
- ✓ Scalpel handle, short (skin)
- ✓ Scalpel handle, long (15FIG)
- ✓ 2 cervical retractor systems e.g. CERCESS™ or similar
- ✓ 2 Langenbeck retractors
- ✓ 2 needle holders
- ✓ 2 surgical tweezers
- ✓ 2 anatomical tweezers
- ✓ Dissection scissors
- ✓ Suture scissors
- ✓ Cobb elevator, large (very important!)
- ✓ Dissector
- ✓ 2 straight rongeurs, sizes 3 and 4
- ✓ Possibly 1 to 2 different bone curettes (not essential)
- ✓ Luer, large
- ✓ Luer, medium



Correct preparation of the required instruments.

### Tip

Instrument the DIANA implant directly from the special trays!

### Additional instrumentation

- ✓ Battery-operated drill with Jacobs chuck or quick-release chuck
- ✓ High-speed drill (rose-head attachment 4–6mm)
- ✓ Bipolar bayonet-shaped forceps
- ✓ Monopolar with long attachment
- ✓ Instruments to remove S1 screws (if necessary)

Optional:

- ✓ Hollow drill to remove iliac crest bone graft (diameter up to approx. 0.7mm). This drill is also available directly from SIGNUS on request.

The content of this checklist is **not** included in the DIANA tray.


## Preparing for the operation

Prerequisites for successful implantation with DIANA are an adequately equipped operating theater, correct positioning of the patient, and clear and precise radiographical imaging. The entire surgery time (incision / suture) is about 90–120 minutes. If the personnel is already experienced in positioning the fluoroscope, this shortens the surgery time accordingly.

### → Surgery positions

The DIANA method requires a radiolucent operating table, a fluoroscope, and a microscope. The figure shows the operating room layout for a patient whose right sacroiliac joint will be treated. The surgeon stands on the opposite side to that being treated.

Configuration of the operating theater for surgery on the patient's **right SIJ** using the DIANA method.



# PRODUCT INFORMATION

## Preparing for the operation

---

### 1 Layout

---

#### a) Operating table with no obstacles (carbon fiber table)

---

- The patient is placed in a standard delordosed prone position using appropriate positioning aids (see page 17).

#### b) Standard operating table

---

- The patient is placed in a standard delordosed prone position using appropriate positioning aids (see page 17).
- A VAC cushion ensures the position is optimized and that the patient is stable.
- The patient must be positioned with the non-operative side far over to the edge of the operating table. This allows oblique radiographic imaging.

#### b1) Position of the metal braces

---

- Depending on the position of the column, the patient has to be positioned very far towards the foot or head end.

#### Caution

The pelvis must not be positioned at the level of the column because radiographic imaging is otherwise not possible!

#### Note

For table tops made completely of carbon fiber, points b) and b1) do not have to be considered.

#### c) Radiographic guidance

---

- AP
- Oblique (for checking the positioning)
- Lateral

#### d) Fixation

---

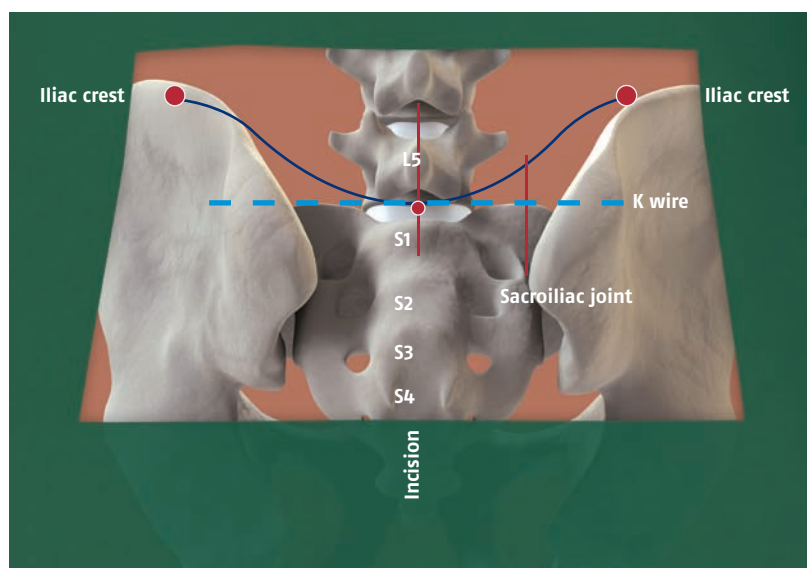
- Following this, the anesthetist can optimally secure the position and organize the placement of any other necessary aids.

## 2 Patient positioning

Proper positioning of the patient is imperative for both access and intraoperative imaging. For this purpose, the patient is positioned on the radiolucent operating table in a prone position.

**Important:** The patient must be placed in a stable position to avoid too much lordosis in the lumbar spine because this makes the visualization and exposure of the recess difficult. The use of a vacuum cushion around the lumbosacral transition with a delordosed position has proven useful. The landmarks for the incision are located using radiographic imaging and a wire and are marked on the skin: the midline and the upper edge of the sacrum form almost the center of the skin incision. From this point the incision is made 3cm cranially and 2cm caudally. The fenestration of the surgical drape must extend at least 8cm laterally from the midline to the point at which the posterior superior iliac spine is at its widest and is subcutaneously prominent.

Instruments and materials that are not included in the DIANA tray can be prepared using the checklist (see page 20).



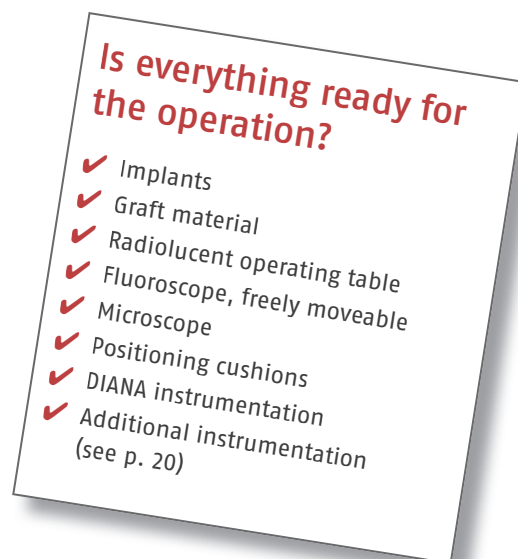Marks and incision site for an operation using the DIANA method on the right side of the patient.

## 3 Fluoroscopic positioning

- The fluoroscope is located on the correct side. ✓
- The patient data have been recorded. ✓
- The spine is selected using pulsed fluoroscopy. ✓
- The position is correct. ✓



The operation can start.





# PRODUCT INFORMATION

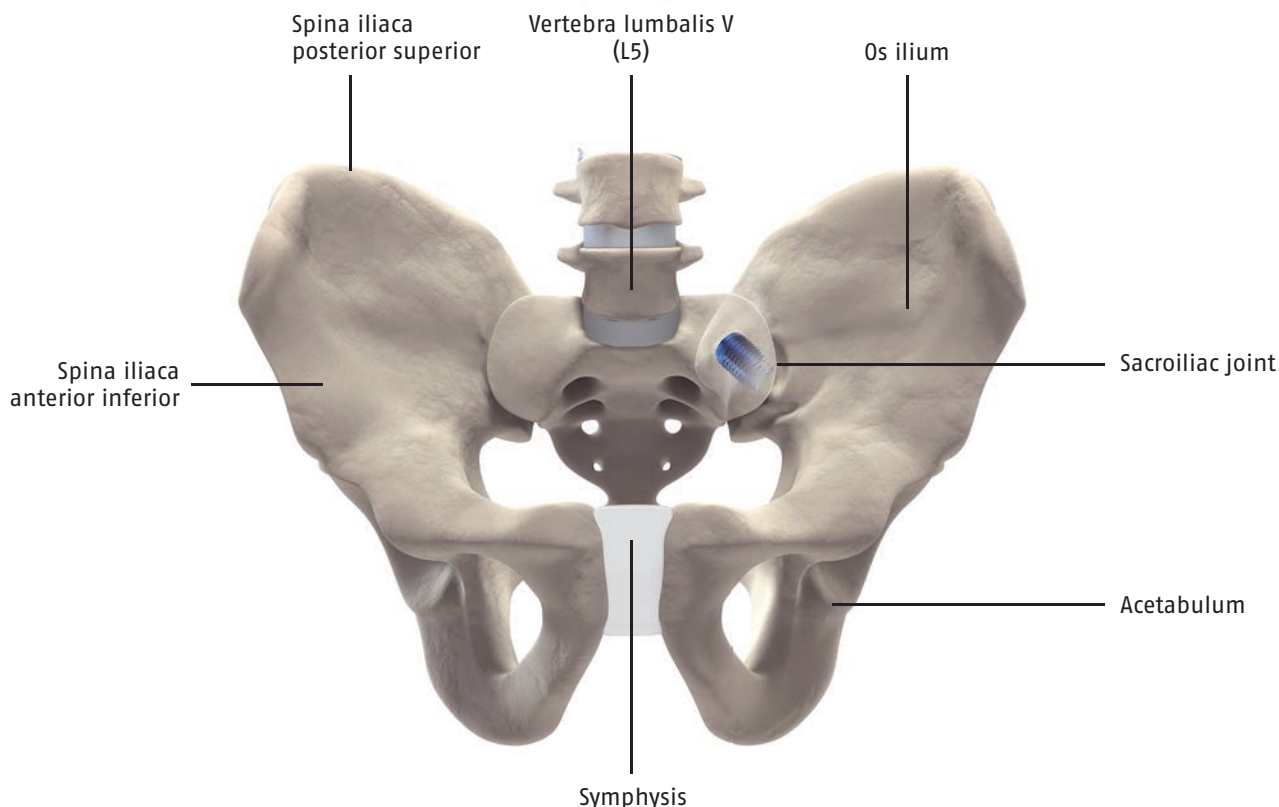
## Intraoperative imaging

---

### Anatomy of the pelvis

---

- The patient is placed in a prone position.
- The legs are extended normally, the knees are cushioned, and a foot bolster is positioned.
- The SIJ is displayed with recess, the upper edge of the sacrum, acetabulum, and femoral head (visible in all three projections).



### Fluoroscopy technique

---

- The C-arm and the monitor cart must always be placed on the side of the patient that is being operated on.
- After aligning the C-arm relative to the operating table, it is locked into its working position and its location is marked on the floor using tape. The operating field is then disinfected and the sterile drape is placed over the patient and the C-arm. The automatic dose rate control (ADR) for the C-arm is switched off by activating the stop button.
- All other fluoroscopic images should be done using pulsed fluoroscopic mode (if possible depending on the device).
- The C-arm receiver system must be located as close as possible to the body area being examined for all fluoroscopic images.

### Documentation and archiving

---

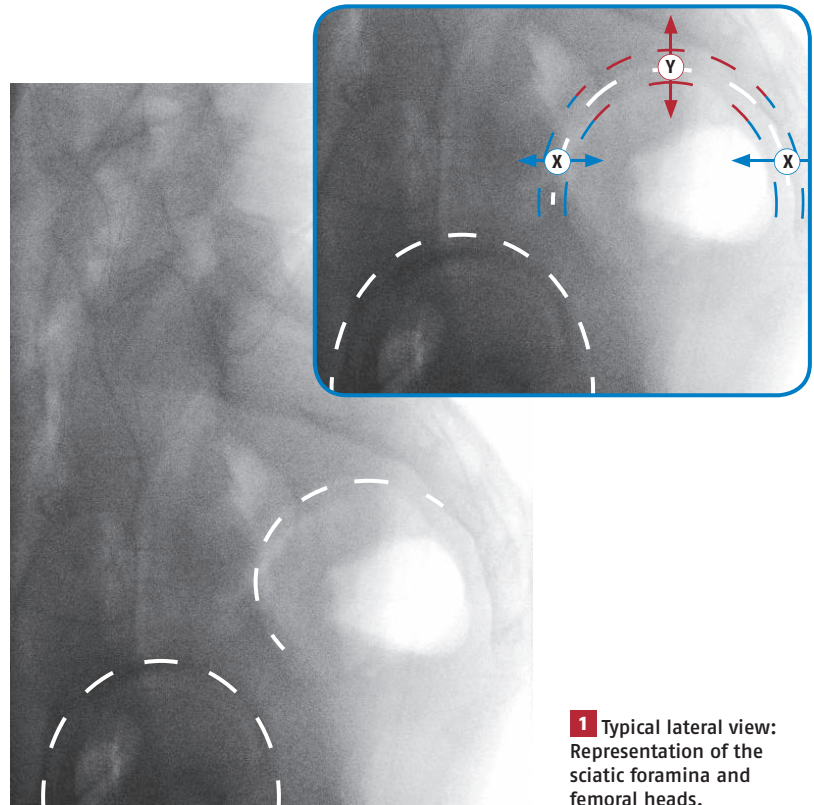
- Total fluoroscopy duration and dose area product.
- Names of radiographer or expert physician carrying out the fluoroscopy.
- The archiving is done using the DICOM standard on appropriate data media for a period of at least ten years.



## Setting up the fluoroscope

### → Aligning the fluoroscope

As soon as the C-arm has been brought into the required starting position for the DIANA method, all necessary views can be prepared. For this purpose, the C-arm must be at a 90° angle to the patient. **2** For better orientation, rotate the lateral view by 90 degrees. **1** The C-arm is now positioned so that the two sciatic foramina are aligned in the lateral view. Double projection would otherwise distort the direction of the trajectory.



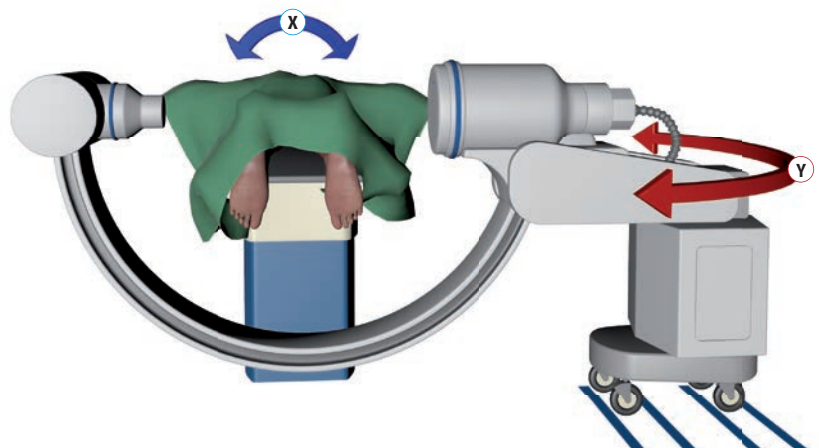
**1** Typical lateral view: Representation of the sciatic foramina and femoral heads.

Adjusting the fluoroscope in case of double projection of the sciatic notches (near side and contralateral landmarks):

**X** = Correction of an anterior / posterior shift (tilt the table).

**Y** = Correction of a superior / inferior shift (adjust the C-arm).

The fluoroscope is aligned before the operation or before the first incision by rotating and adjusting the height of the C-arm. All required views can then be obtained from this position.



**2** Basic adjustment and positioning of the fluoroscope.

# PRODUCT INFORMATION

## Required images

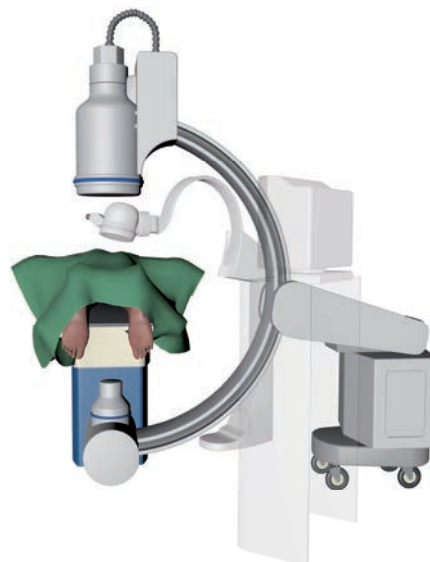---

For implantation of the DIANA system, radiographic views in three planes are required: AP, oblique, and lateral. All these views can be obtained from the previously defined position of the fluoroscope by rotating the C-arm.

### → AP

---

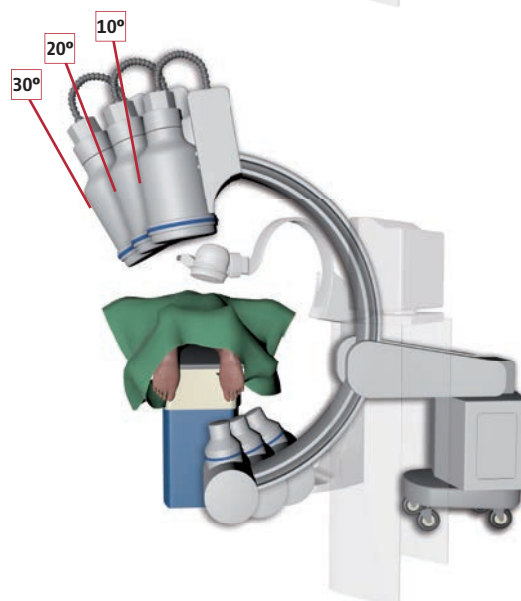
For the AP view of the affected SIJ, the carriage must be pulled back and the ilium, lateral part of the sacrum, and the acetabulum with the acetabular dome are imaged.



### → oblique

---


To obtain the oblique view, the C-arm is rotated in 10-degree steps from 10 to 30 degrees to the midline so that the X-ray beam is directed downwards through the extra-articular space of the SIJ. The final oblique angle is usually less than that of a true Judet view; this is de facto rather an AP view of the recess.



### → lateral

---

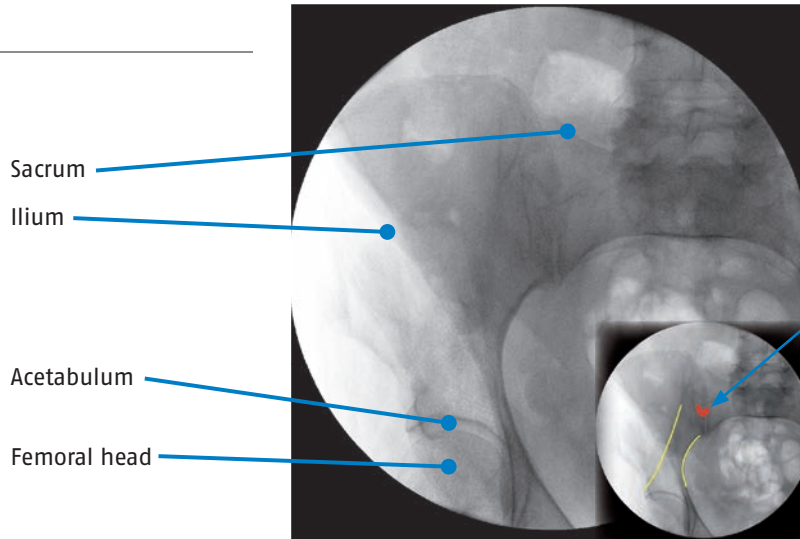
The C-arm is pivoted around for the lateral view and positioned close to the patient. For intraoperative lateral positioning, ensure that the large sterile drape is attached while rotating the arm. The drape should be fixed to the opposite side of the C-arm at the height of the operating table.



## Positioning

Due to its three-dimensional alignment, the SIJ can only ever be viewed in parts in the radiograph.

### AP

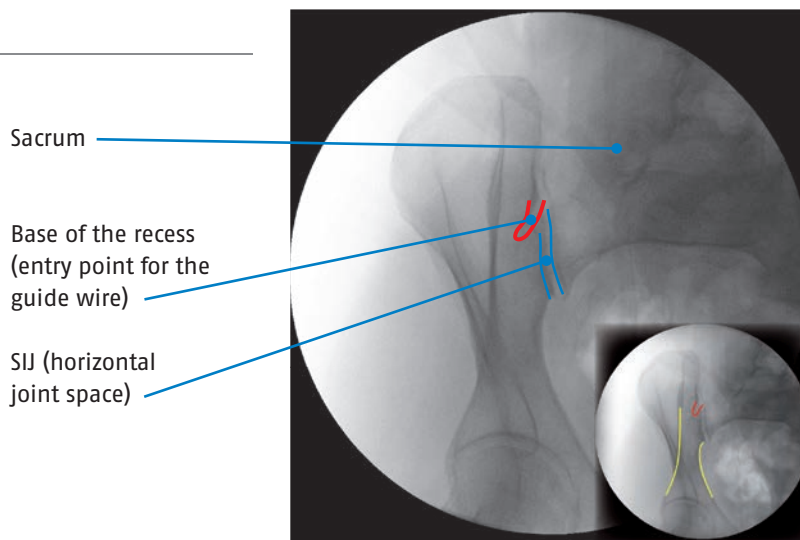


The red mark indicates the base of the recess.

The entry point for the guide wire is located within the area marked.

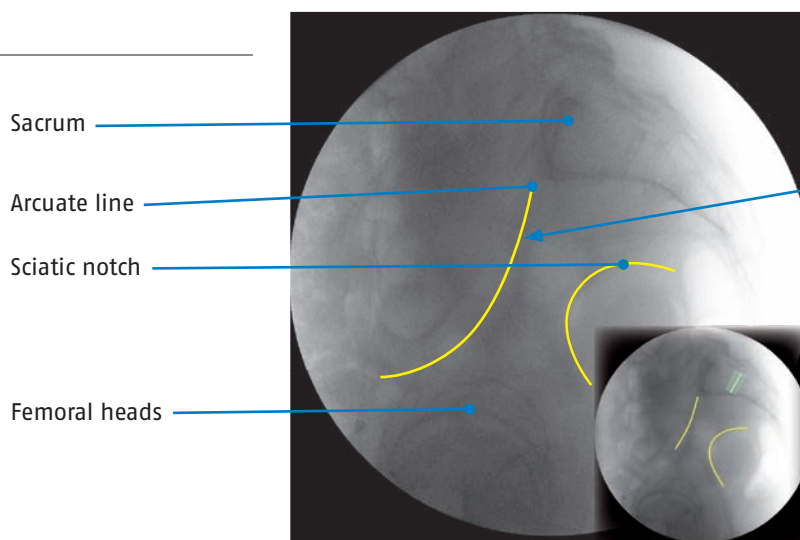
The yellow lines indicate the arcuate line (left) and the sciatic notch (right) respectively.

### oblique 25°–35°



The yellow lines indicate the arcuate line (left) and the sciatic notch (right) respectively.

### lateral



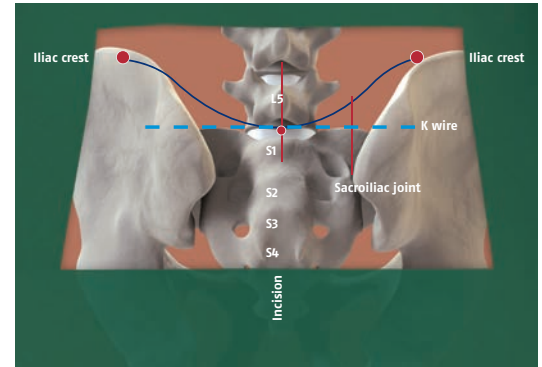
Arcuate line  
Sciatic notch, here shown congruent.

The light blue line shows the entry point of the guide wire at the height of S1/2 of the intervertebral disc.

# PRODUCT INFORMATION

## Surgical technique

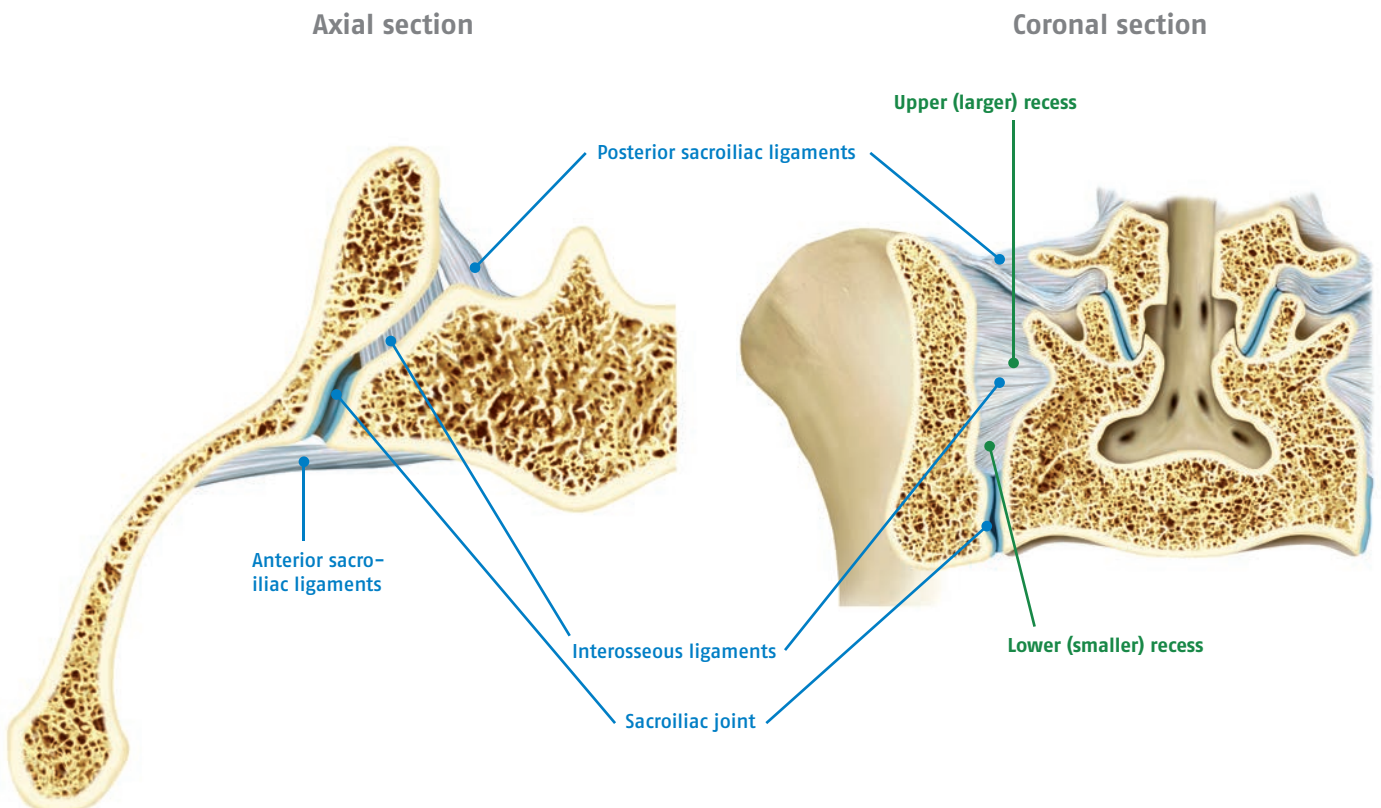
- First, ensure that all instrumentation (including general instruments), the fluoroscope and the consumables are prepared.
- Radiographic and CT images should be used to confirm the indications and to check for adequate bone quality, post-traumatic bone deformities or special anatomical features as part of the preoperative surgical planning because the size, shape, and alignment of the recess are extremely variable.
- Any implants such as iliosacral screws or S1 pedicle screws must be removed if they are blocking the access routes for the instrumentation. As part of the preoperative planning, it must be ensured that appropriate instruments for removal of any metal components are available.



Marks and incision site for an operation using the DIANA method on the right side of the patient.

## Anatomical landmarks for the operation

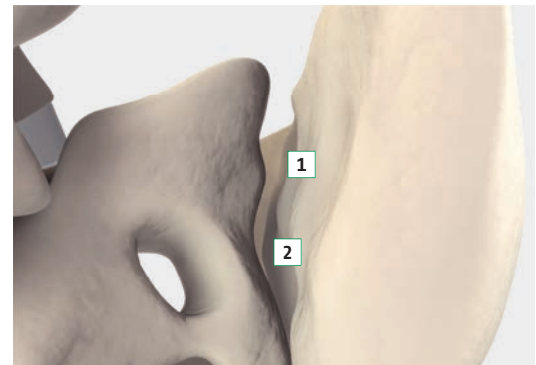
The recess located behind the SIJ is divided by the S2 transverse process into a larger upper (between S1 and S2) and a smaller lower (between S2 and S3) preformed spaces. The interosseous ligaments, which are resected during the dissection, are located here.





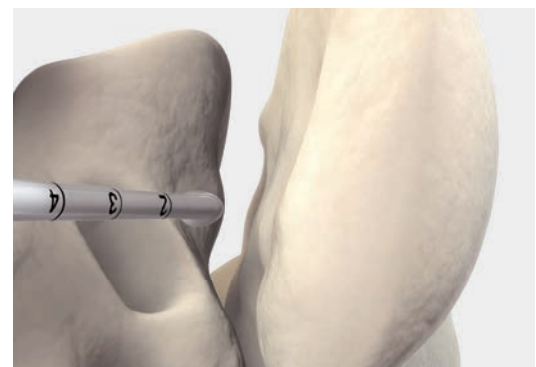
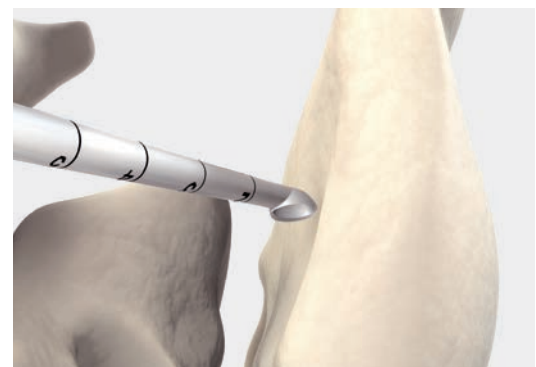
## 1 Access and dissection of the recess

- First, the height of the skin incision must be determined.
- An incision about 5cm long is made down to the thoracolumbar fascia.
- A sharp retractor that can curve through a joint is then used.
- The dissection is then made epifascially in a lateral direction to the posterior superior iliac spine (PSIS) on the affected side.
- After identifying the posterior superior iliac spine (PSIS), a fascial incision offset about 1.5cm towards the midline is made. This runs about 1.5cm caudally to the skin incision.
- A second bendable retractor is inserted after blunt dissection of the musculature to the posterior sacroiliac ligaments.
- Access to the recess is done by preparing along the ilium. This is done with a Cobb elevator and identification of the upper recess using the trampoline effect.
- With a scalpel enter the recess at an angle of about 45 degrees in a lateral direction to the ilium. The posterior sacroiliac ligaments are resected via the larger upper recess; from here the entry is made with the bone curette.
- AP and oblique radiographs are used to confirm the correct position.
- These steps are carried out using the microscope.
- Using the large straight bone curette from SIGNUS, the medial iliac wall is dissected along the entire extent of the recess from cranial to caudal to the recess base. This process requires extreme care and must be done beneath the fascial attachment. During the process the attachments of the longissimus muscle must not be damaged or detached. For this purpose, the bone curette is moved back and forth along the medial wall until it meets the angle between the sacrum and the ilium at the bottom.
- Using a rongeur, the soft tissues are carefully removed. First, the sacral cortical bone is freed from the remaining attached interosseous ligaments until the cortical bone can also be seen. Injuries to the cortical bone must be avoided!
- Then, the lower narrow part of the recess is dissected free using the smallest bone curette. After the recess has been completely cleared out, parts of the joint space (vertical) between the iliac and sacral cortical bone should be visible.



1 = Upper recess

2 = Lower recess



### Caution

The dissection of the recess must be done under microscopic guidance!

## 2 Localization of the SIJ at the distal aspect of the recess

It is not necessary to advance into the joint itself via the extra-articular recess. At the bottom of the recess the two joint surfaces intersect it at an angle that blocks the view into the joint itself. After careful exploration, the space lying directly lateral to the transverse process, which serves as the entry point for the guide wire, can be identified.

# PRODUCT INFORMATION

## Surgical technique

Using a high-speed drill the surfaces of the recess are debrided using a 5mm rose head while ensuring that the surface anatomy is preserved. The cortical bone is opened using punctate application of the drill with the rose head attachment being inserted into the bone to about half its height, thus exposing the cancellous bone surfaces for subsequent fusion. The distances between the resultant crescent shaped cortical lesions can be very small in the upper part of the recess to ensure a more rapid bony union. However, in the lower part of the recess it must be ensured that there is sufficient cortical bridges remaining to enable distraction between the sacrum and the ilium using the implant.

### 3 Preparation of the bone

Tips for preparing the bone substitute material\*:

- 30cc (chips of 2 to 4mm each) of homologous cancellous bone is preferable or 1 to 2 half femoral heads.
- About 10ml of venous blood or blood from the site is required.
- Using a hollow drill about 3cm (bone cylinder) of iliac crest bone graft from the ilium is harvested as required.

The harvested materials are mixed together and filled into four 5ml syringes. The tapered tip of the syringe should be cut off at the 0.2ml mark.

#### Bone apposition

##### Caution

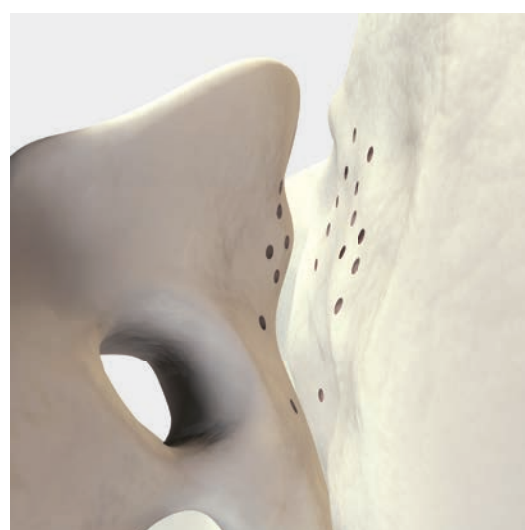
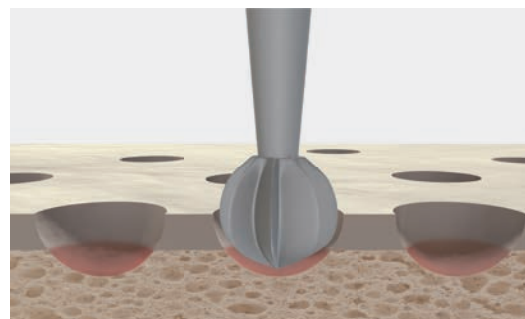
The decorticated recess must be considered as a bone defect that is treated without compression from the adjacent bone surfaces.

For this reason it is absolutely essential to adhere to all principles of bone healing in particular as it relates to preparation of the corresponding surfaces of the ilium and sacrum and the use of osteoconductive and inductive materials.

The bone graft is now placed directly into the recess on the adjacent surfaces of the ilium and the sacrum. The deepest and narrowest point (the base of the recess) must be filled with the bone graft and the material must be packed into the base using a narrow tamp, a dissector or anatomical forceps. This is done to ensure that no voids remain around the implant. The exposed and debrided surfaces must be covered. The transplant itself should not protrude above the level of the posterior ilium or the cranial margin of the recess. During wound closure it is covered by the fascial suture.

#### Positioning the initial guide wire

The step to position the implant is done at about the height of the S2 transverse process. The 2.4mm diameter blunt guide wire is placed through the guide sleeve to the base of the recess. This is done under radiographic guidance in all three planes. In its extension the target of the guide wire is always the middle to lateral part of the acetabulum.



Decortication area.

\* The indication, selection and implantation lies in the responsibility of the user surgeon and must be individually be adapted to the patient's needs.

Having verified the correct trajectory in the three planes, the blunt guide wire is replaced by the threaded 3.2mm guide wire and fixed with gentle strikes of the mallet into the cortical bone of the ilium. After another radiographic check in three planes, the guide wire is then stretched in the chuck of the drill and predrilled a maximum of 2cm above the anterior edge of the sacrum. The guide wire is now fixed firmly in the ilium by its thread. The wire thus provides the orientation for the instrumentation.

### Caution

The position of the guide sleeve must not be altered when replacing the wire!

### Controlled distraction and determining the size

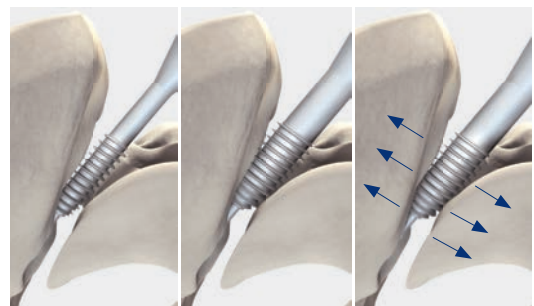
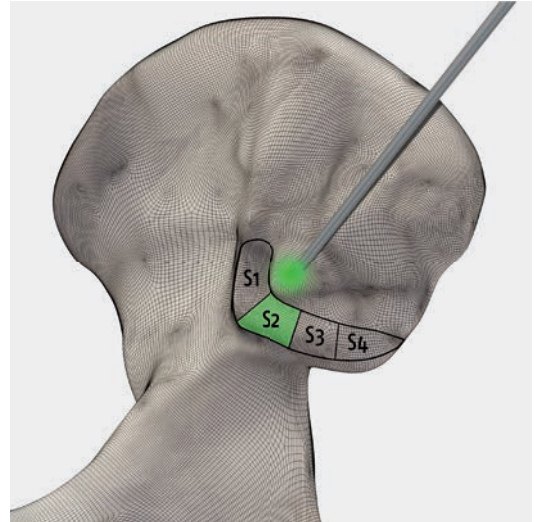
The smallest helio, 13mm, is now placed over the guide wire and introduced into the recess. While turning it is advanced until noticeably increasing resistance is felt indicating that it is firmly gripping the cortical bone of the recess. To move from the posterior edge to the anterior edge of the sacrum requires about 20 half-rotations. The position of the helio should be checked radiographically at the start of the distraction process and after ten half-rotations of the instrument. Generally, after another ten half-rotations the tip of the helio is located at the anterior edge of the sacrum (in the lateral image).

Depending on the bone resistance and ligamentotaxis, it must be decided whether the next larger distractor will be used.

### Caution

It may be that the smallest helio (13mm) cannot be engaged. In this case the access should be carefully opened to the anterior edge of the sacrum using the smallest iliac drill (predrill).

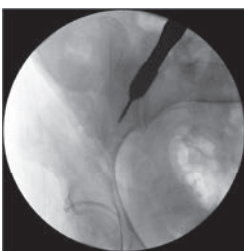Depending on the resistance encountered it must be decided whether or not the next larger helio will be trialed. Increased helios may be used until the final size is chosen – determined by firm resistance in the final third of its insertion. The tip of the helio should be positioned in front of the anterior edge of the sacrum. The T-handle is then removed.



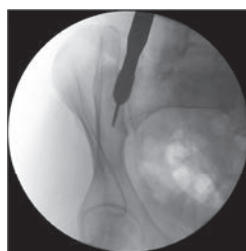
Helio too small.

Helio correct.

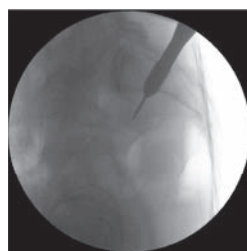Controlled distraction.



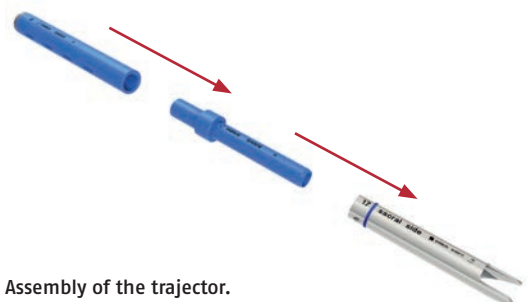
AP view.



Oblique view.



Lateral view.



Assembly of the trajectory.

# PRODUCT INFORMATION

## Surgical technique

### Note

The helio itself does not have a tapping flute. It distracts the ilium relative to the sacrum and thus the joint space.

### The distraction has the following effects:

- Separation of painful joint surfaces from one another
- Stretching of the ligamentous structures (ligamentotaxis)
- Elimination of sites of subluxation of the SIJ
- Possibly relieving pressure on affected nerve roots (L5 and / or S1).

### Maintaining the distraction

The trajector maintains the distraction. The correct size (color) corresponds to that of the final helio.

To protect the softer bone of the sacrum during the trajector's insertion the instrument is shaped asymmetrically. Together with the anti-subsidence shoulder of the implant, this design is responsible for maintaining the distraction preventing subsidence of the implant into the sacrum.

The trajector is oriented with the sacral side facing the sacrum (see marking on the instrument). Before inserting the trajector the lateral image should be checked. This ensures that the narrowest side of the blades of the recess wedge can be seen. If this is not the case, the wedge must be rotated into the correct position. The trajector is then impacted until it is firmly seated, however, it should not be further forward than the anterior edge of the sacrum. The impact sleeve and the helio can now be removed.

### Reaming the implant bed

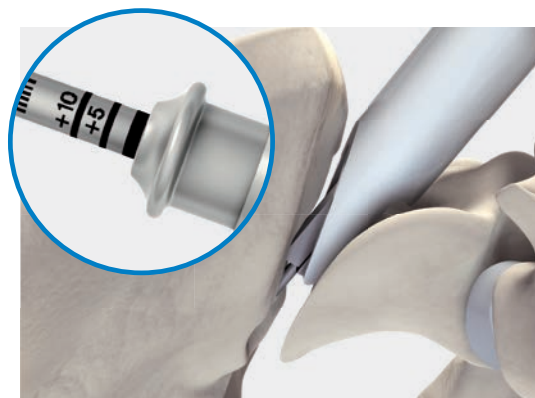
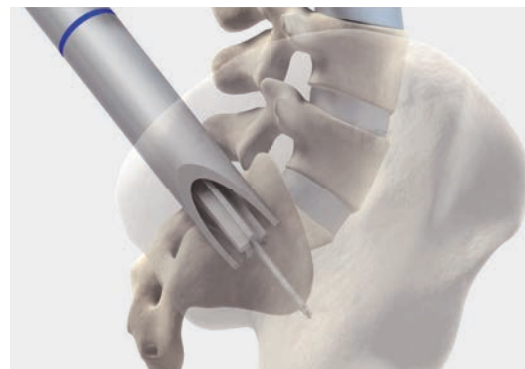
The reamer corresponding to the helio diameter is fitted with a depth stop. First, set it to the standard depth (zero position, bottom-most mark), which corresponds to it stopping at the anterior end of the trajector.

The upper marking on the reamer (+10) implies that the tip of the reamer will advance to 10mm anterior to the leading edge of the trajector. It is also possible to fix the depth stock between the two markings (+5mm).

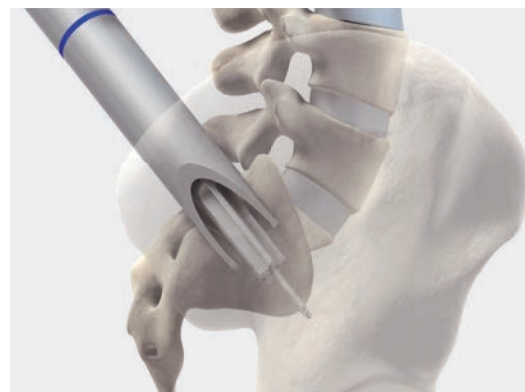The T-handle is now mounted on the reamer and it is introduced over the guide wire into the trajector. The reamer is advanced while turning the instrument until the depth stop contacts the proximal end of the trajector. The depth stop prevents the instrument from cutting too deeply into the ilium. In patients with poor bone quality it may be appropriate to select a reamer that is one size smaller than that specified by the color-coding so that the implant will fit tighter.

### Example:

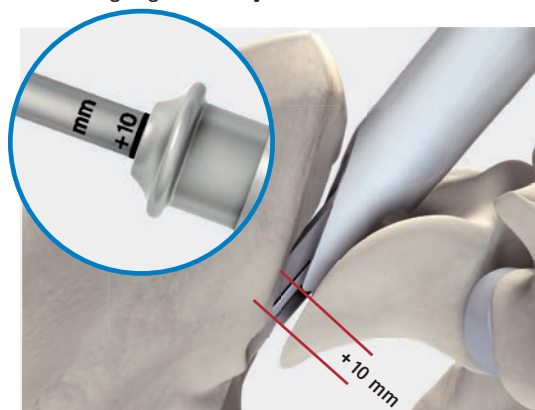- Helio size 15 (yellow)
- Recess wedge (yellow)
- Drill 13 (magenta)



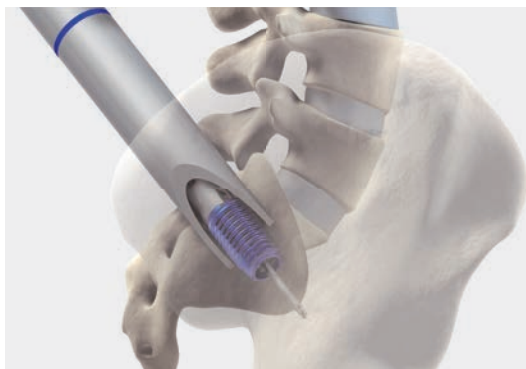
Depth stop '0' implies the reamer ends at the anterior edge of the trajector.



Depth stop '+10' implies the reamer ends 10mm anterior to the leading edge of the trajector.



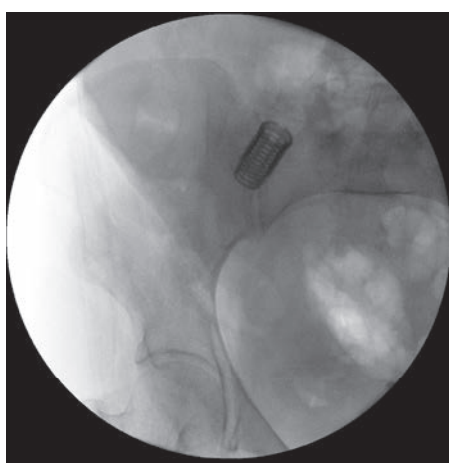
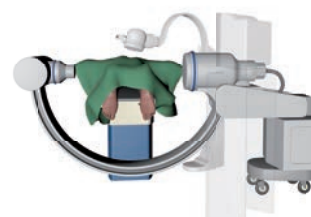
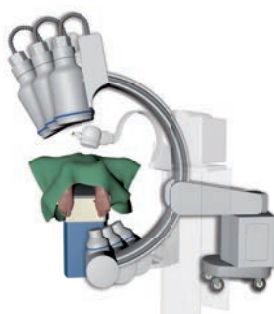
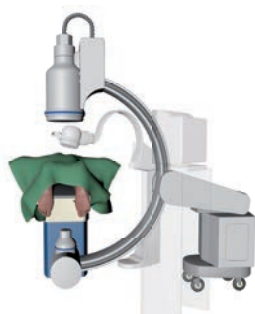


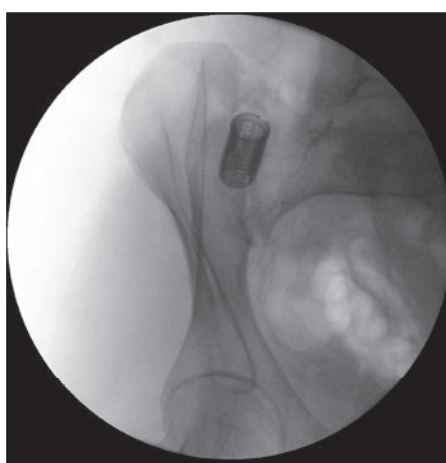
## 4 Implantation and bone transplantation

The implant size corresponding to that of the helio is loaded on its respective color-coded inserter. After attaching the T-handle, the implant is inserted over the guide wire. The implant is advanced under fluoroscopic control (lateral view) until it is seated in the desired position.

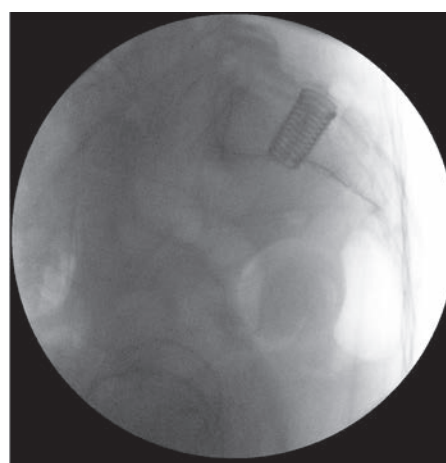
The inserter is now withdrawn by pulling back on the T-handle. The guide wire is removed with the battery-powered drill and the trajectory is withdrawn with the slap hammer. The implant and the extra-articular space are now carefully filled with bone material. When doing so, ensure that the bone material completely fills the recess distally and proximally as well as the implant itself. Before final closure of the wound, the position of the implant must be checked fluoroscopically in all three planes.



Final position of the DIANA implant AP.



Final position of the DIANA implant oblique.



Final position of the DIANA implant lateral.

# PRODUCT INFORMATION

## Sample operative report

### Data

Date of surgery:	<input type="text" value="MM.DD.YYYY"/>	
Patient:	<input type="text" value="First name, last name"/>	Date of birth.: <input type="text" value="MM.DD.YYYY"/>
Surgeon:	<input type="text" value="First name, last name"/>	
Assistant:	<input type="text" value="First name, last name"/>	
Diagnosis:	Primary (M19.05)/secondary SIJ osteoarthritis (M19.25)	<input type="text" value="right/left; secondary diagnoses"/>
	<input type="text"/>	
Operation:	Distraction interference arthrodesis of the sacroiliac joint (DIANA, SIGNUS Medizintechnik GmbH) (5-808.0 Arthrodesis: sacroiliac joint)	<input type="text" value="Size 13/15/17/19 mm"/>
	<input type="text"/>	

### Operation sequence

The patient is positioned in a prone position. Positioning the fluoroscope in all three planes and determination of the skin incision with the help of a wire under fluoroscopic guidance to define the upper edge of the sacrum. Usual surgical field preparation with disinfection and sterile draping of the surgical area.

The access is opened to the fascia via a midline incision of approximately 5cm length.

The subcutaneous tissue is pushed away from the fascia down to the posterior superior iliac spine (PSIS) and the recess. The fascia is opened up about 1 finger width medial to the PSIS along the fibers. Bluntly force apart of the musculature. Placement of the Cobb elevator on the ilium and sliding in a medial direction into the "soft spot" of the ligamentous apparatus over the posterior recess. At this site, resection of the posterior parts of the sacroiliac ligaments with the rongeur until the recess can be visualized. The recess is then carefully curetted until the joint space can be visualized in readiness for apposition of the bone material.

Using a high-speed drill, several punctate holes 3-5mm in size are drilled in the medial side of the ilium and the lateral side of the sacrum to expose the medullary cavity. The previously prepared homologous cancellous bone is inserted into the prepared recess down to its base and then lightly compacted. The homologous bone graft was also mixed with autologous cancellous bone that was removed from the ilium using a hollow drill. The harvest site in the ilium is filled with cancellous bone.

The direction of the instrument is now determined with the blunt guide wire under fluoroscopic guidance. The guide wire is inserted under fluoroscopic guidance and advanced to the ilium under fluoroscopic guidance.

The guide sleeve is then inserted into the recess via the K wire, the K wire is removed and replaced by the cutting guide wire. The wire is advanced about 2cm into the ilium with the drill. After radiographic verification in three planes (AP, oblique, lateral), the guidance aids are removed.

The smallest (13mm) helio is now inserted via the guide wire and the joint is distracted. After 10 complete rotations (corresponds to 3cm advancement), the next larger size is used until the resistance clearly indicates that the helio is firmly seated. In this case this was size .

The distal end of the helio is seen at the height of the anterior edge of the sacrum in the lateral radiographic check.

The distraction is maintained with a  trajector of the same size by advancing the trajector over the helio until it is seated.

The helio is removed, and the trajector and the guide wire remain in place. A reamer of the same size or a smaller size is advanced with the depth stop to a depth of .

Removal of the reamer. The  implant is inserted into the recess via the guide wire using the inserter and rotated to the correct final position.

Removal of the inserter, the guide wire, and the trajector. The radiographic check shows proper seating of the inserted implant. The implant and the rest of the recess are now carefully filled with the remaining cancellous bone. The bone material is compacted solidly and a subfascial drain is placed.

Layered wound closure of fascia, subcutaneous layer, and skin.

Application of a sterile wound dressing.

## Postoperative treatment

- Redon drain and indwelling catheter removal on postoperative day two.
- If necessary, CT and pelvic view, postoperative partial weight bearing on the operated side with 20kg for 8 weeks with underarm crutches.
- Continue with low-molecular-weight heparin throughout partial weight bearing.

Signature

**An extensive bipolar denervation of the right SIJ concludes the procedure.**

**Insertion of a subfascial redon drain, intracutaneous suture/skin staples.**

## Postoperative treatment

The following steps should be carried out for the follow-up treatment\*:

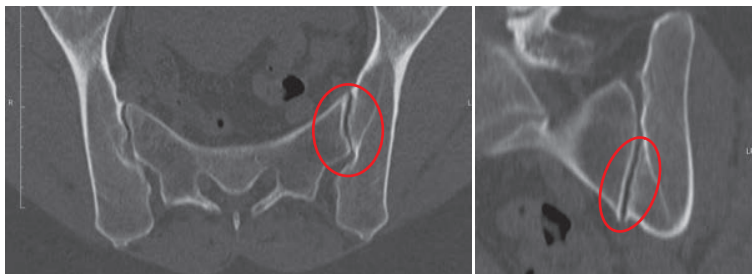
- Removal of the redon drain and indwelling catheter on day 2 after surgery.
- Partial weight bearing of the leg on the treated side with 20kg for eight weeks using underarm crutches.
- Anti-thrombotic prophylaxis over eight weeks.
- Vitamin D substitution over three months.
- Due to possible delayed bone healing, no NSAIDs!
- Preparation of a pelvic view and, if necessary, postoperative CT of the pelvis (checking the position and extent of the deposited homologous bone).
- No physical therapy!
- The patient should avoid bending, spreading the legs, and lifting heavy loads for a total of six months.
- After nine to twelve months, another CT is recommended for radiographic verification of the bony fusion.

\*The indication, selection and implantation lies in the responsibility of the user surgeon and must be individually be adapted to the patient's needs.

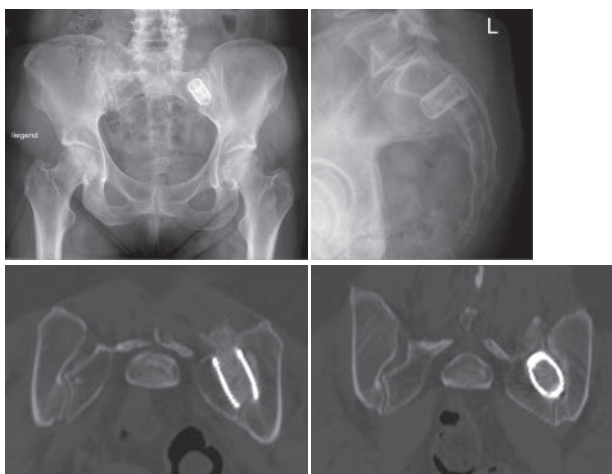
# PRODUCT INFORMATION

## Case study

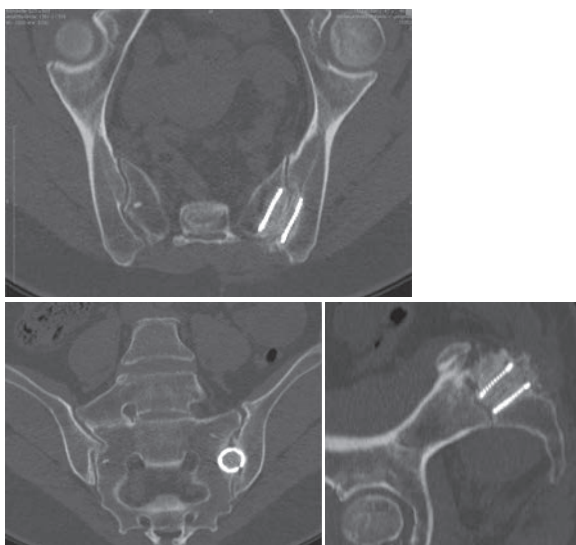
Dr. Volker Fuchs M.D., AMEOS Hospital, Halberstadt (Germany)



CT SIJ pre-OP.



DIANA (19 mm).



CT 6 months.

The following case study reveals the importance of the physical examinations when determining the surgical indication:

### Patient:

- 46 years old, female
- Profession: chef
- Lumbar SP symptoms since 2001
- Regular physical therapy (MT)
- Fall in 1/2010; clear increase in sitting pain symptoms radiating out from the left buttock and upper leg, intermittent in the left calf
- Sitting pain intensifies with sitting and lying on the left side
- Unable to work

### Findings:

- Natural gait pattern
- No tenderness to palpation or percussion of the lumbar spine
- Clear tenderness to palpation of the left SI joint, figure four test +, Mennell's sign + internal rotation sitting pain in left hip joint
- Bilateral straight leg raise, no neurological deficits
- VAS 9.5/10 (back)
- VAS 8/10 (leg)
- Hemisacralization L5 right (!)
- Spondylarthrosis L3–5 accentuated on the left
- Slight fixation of listhesis L3/4

### Injection:







- 1st injection into left SI joint recess → 80% SP reduction for 24h
- 2nd injection into recess and 1st injection into SI joint with CA → almost pain free for 36h







### 7 months post-OP

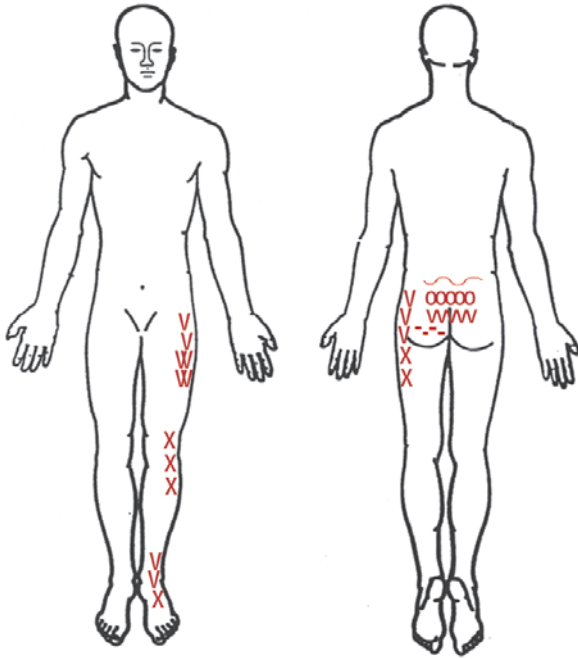
- Preoperative pain considerably improved
- VAS 3.5/10 (back)
- VAS 0.5/10 (leg)
- After more than 4h work, intermittent, short-lived, stabbing SP
- Pain no longer radiates in the left leg
- Can lie on the left side again
- "Everything is better than before"
- Can work again
- SIJ arthrodesis union in the CT

### List of abbreviations

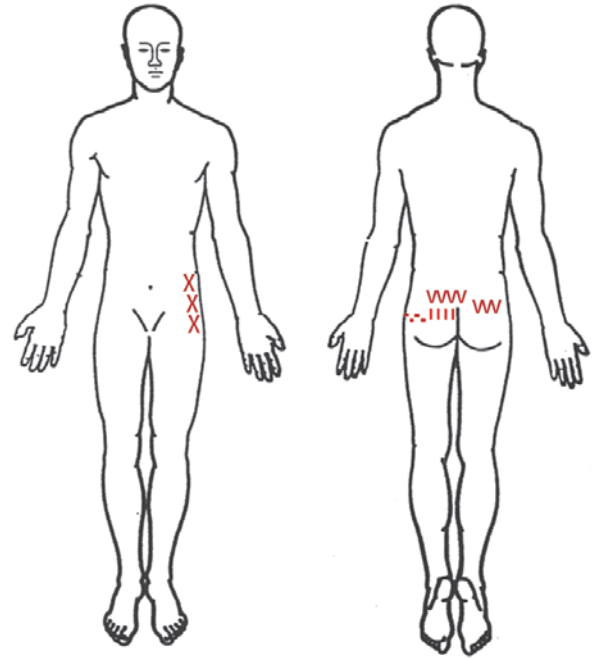
TTP	tenderness to palpation
IR	internal rotation
CA	contrast agent
TTP	tenderness to percussion
MT	manipulative therapy
SP	pain on sitting

Numbness =  Burning =  Pricking =   
 Painful =  Stabbing =  Taut = 

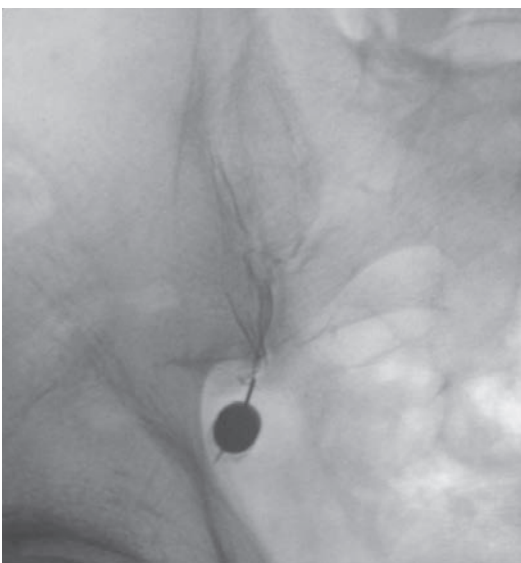
Numbness =  Burning =  Pricking =   
 Painful =  Stabbing =  Taut = 



Pre-OP pain drawing.



Post-OP pain drawing.



Injection.





**NOTE:** This document was written by the technical department at SIGNUS Medizintechnik GmbH. Despite being reviewed by trained personnel, the sole purpose of this brochure is to provide an explanation of the technical aspects of handling the product described. This document, in particular the description of the surgical procedure, should not be considered medical scientific literature.

**SIGNUS Medizintechnik GmbH**

Industriestr. 2  
63755 Alzenau/Germany

Tel: +49 (0) 6023 9166 - 0  
Fax: +49 (0) 6023 9166 - 161

info@signus.com  
www.signus.com


**SIGNUS Australia Pty Ltd**

Suite 12/133 Alexander St.  
Crows Nest, NSW 2065

Phone: +61 (0) 2 9973-2771  
Fax: +61 (0) 02 8088 4766

info@signus.com.au  
www.signus.com.au

**DIPLOMAT®**  
Thoracolumbar posterior instrumentation



Augmentable posterior pedicle screw system

**MOBIS® II ST**  
Transforaminal Lumbar Interbody Fusion



TLIF Cage

**ASCOT®**  
Anterior cervical stabilization



Cervical Plate System

